

**W**hen it comes to front end lameness, there are two words certain to fill any horse owner with dread: navicular disease. Such apprehension is understandable. Until recently, a diagnosis of navicular disease meant chronic lameness, loss of usefulness, and expensive, special shoeing that might help for a while – or not at all. Owners trying to understand the condition faced a labyrinth of conflicting information, making it difficult to know what treatment and prevention strategies were best. Ultimately, a horse with navicular disease could be expected to deteriorate to a point where euthanasia would be the only option.

Fortunately, recent advances in the understanding and application of correct hoof biomechanics are raising the possibility that many previously doomed horses may be rehabilitated to a comfortable and useful life. In addition, recent research – and the re-examination of older research – is shedding new light on this condition. Though there is still much to learn, many now believe that the lives of a significant number of navicular horses can and will be saved if horse owners can get a clearer understanding of navicular disease, and the new treatment and prevention options available to them.

BY SUSAN KAUFFMANN

#### DEFINING NAVICULAR DISEASE

People often hear the terms “navicular disease” and “navicular syndrome” used interchangeably, but they in fact have different implications. Navicular disease has traditionally referred to degenerative changes in the navicular bone that have been confirmed by radiography (X-rays). Horses with radiographic evidence of navicular disease may or may not demonstrate lameness – a fact that remains a source of great confusion. As for the clinical symptoms, they include:

- chronic, progressive lameness in one or both forelimbs
- short or shuffling gaits, often with a toe-first landing
- sensitivity to hoof testers on the central third of the frog
- relief from pain when a nerve block is applied to the palmar digital nerve
- frequent shifting of body weight when resting
- resting the affected foot on the toe (“pointing”)

Adding to the confusion surrounding navicular disease, horses may exhibit some or all of the clinical symptoms, yet show no radiographic evidence of the problem. This is the scenario often referred to as “navicular syndrome.” Many researchers, veterinarians and farriers, however, would prefer to see this phrase dropped from the horseman’s lexicon. As renowned veterinary researcher and author of *The Lamé Horse*, James R. Rooney, DVM, states: “The term ‘navicular syndrome’ is both a misnomer and misleading. What is being said is that there is pain in the foot and the speaker does not know the cause or site of the damage.”

#### NEW RESEARCH

Those who take issue with such vagueness will no doubt be pleased that recent clinical studies using magnetic resonance imaging (MR) have provided veterinarians with a technique to diagnose navicular disease more precisely than ever before. This is because MR provides extremely detailed images of soft tissue structures, such as

*Recent research and advances in understanding the hoof offers hope for owners with horses suffering from navicular.*

# NEW THOUGHTS ON NAVICULAR SYNDROME

The extensive devastation caused by navicular gives rise to powerful new study developments.

ligaments and tendons, that could not previously be seen with other imaging techniques, as well as giving much more detailed images of bones. In a paper presented to the American Association of Equine Practitioners, researchers R. K. Schneider, P. R. Gavin and R.L. Tucker of Washington State University writes: "MR has added to our knowledge of navicular disease, in large part, because for the first time we can see into the horse's foot." Though new studies like this cannot be taken as definitive, the conclusions of the WSU team have received a great deal of interest from scientists and equine practitioners.

The WSU MR studies demonstrated that there are changes in the soft tissues that occur in association with navicular disease long before anything could be seen with conventional radiography, and they also detected bone abnormalities in cases where conventional radiographs were normal. Furthermore, their observations strongly support what many equine practitioners have long suspected – that there are various problems in the foot that could cause clinical signs similar to those seen with true navicular disease. As Dr. Rooney says, "Navicular disease is grossly over diagnosed." However, that is likely to change as the new MR technique becomes more widely used.

The problems WSU researchers distinguished from navicular disease were inflammation of the ligaments and deep digital flexor tendinitis, both of which can produce symptoms identical to navicular disease and would likely be diagnosed as such without the use of MR. The researchers only diagnosed navicular disease if they found excessive fluid in the navicular bone, which is not present in normal horses. They state: "Unlike radiographic changes, which for the most part do not correlate with clinical signs, fluid in the bone on MR was observed to correlate with clinical signs. The most fluid and the most obvious abnormalities were in the lamest leg."

The important findings of the WSU team have also led to changes in the treatment of horses with navicular disease, as well as those horses that were previously incorrectly diagnosed with the condition. As the researchers state: "Horses with DDF tendinitis have increased options for treatment that have not previously been used or have not been routinely recommended for horses with navicular disease." Specifically, the researchers have found that horses with DDF tendinitis near the navicular bone improve when anti-inflammatory medications are injected into the digital flexor tendon sheath. Being able to differentiate inflammatory problems from navicular disease also helps determine whether a horse should be rested from work

or not. Rest is not traditionally recommended for horses with navicular disease, but may benefit horses with soft tissue inflammation. In addition, the ability to pinpoint what and where abnormalities are present in horses with navicular disease can help veterinarians decide which horses are the best candidates for other treatment protocols.

### THE CAUSE: A NEW (AND NOT NEW!) THEORY

Most experts feel that there are probably a number of factors that can lead to navicular disease. However, one theory is gaining ground as a result of new research and the fact that some hoofcare practitioners claim that putting this theory into practice can save the lives of horses that would previously have been put down or at least retired because of navicular disease. Ironically, this theory is not new, but has been largely overlooked until recently. First put forward years ago by Rooney, the theory suggests that the unnatural toe first landing seen in many domestic horses – and the unnatural forces, rocking and vibration that result – is the primary cause of navicular disease, not the other way around, as has long been argued.

In other research involving post mortem examinations of literally thousands of horses, Rooney demonstrated that it is not, as widely believed, the navicular bone which becomes damaged first and then damages the deep flexor tendon by rubbing on it. In fact, what he found was that damage occurs first to the fibrocartilage (a matrix of cells and collagen fibers) on the surface of the navicular bone and to the fibrocartilage in the deep flexor tendon; then the deep flexor tendon itself; and finally, the navicular bone. Damage to the fibrocartilage in the deep flexor tendon and on the surface of the navicular bone was always present if the bone was damaged, but Rooney found not one case in which there was navicular bone damage without deep flexor tendon damage, which he would have found if bone damage was the first thing to occur.

His conclusions about both the toe first landing and the order in which damage occurs were strongly supported by another experiment he conducted. He took the healthy legs of dead horses and put them in a testing device that simulated a toe-first landing. Tellingly, those legs developed fibrocartilage damage identical to the damage he had found to be the first evidence of navicular disease in his post-mortem examinations.

Why, exactly, the toe first landing is so harmful is perhaps best explained by Pete Ramey, a highly respected leader, author and instructor in barefoot hoofcare. Ramey says, "During normal, heel first movement, the

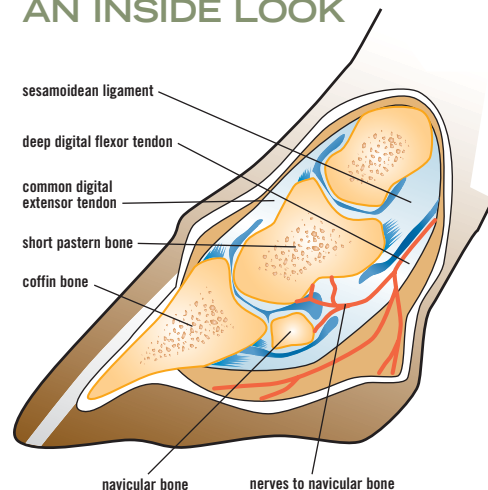
deep flexor tendon is quickly tightened by the descending fetlock joint. At the same time, the coffin joint is rotating forward toward breakover, and is loosening the deep flexor. In a toe first landing, however, the descending fetlock is still tightening the tendon just after impact, but after impact, the heel rocks down, tightening the tendon simultaneously. Understand that in a heel first landing we have one pulley tightening as the other is releasing tension, but with a toe first landing, both pulleys are tightening at the same time. Far greater force is directed to the navicular pulley than was ever intended by nature. This is a very big difference, adding greatly to the force applied to the tendon and navicular bone. Greater force means greater friction, and the continued repeat of this insult causes damage to the region. These are major findings that Dr. Rooney has known and documented for years."

Unfortunately, Rooney's work did not initially receive widespread recognition it deserved, most likely because the evidence he presented demanded a radical re-examination of hoof care and veterinary practices that few were prepared to undertake. As Ramey says, "Dr. Rooney proved and published that it was actually the unnatural toe first movement (usually caused by avoiding heel pain) that causes navicular remodeling; not the other way around as most professionals thought. Understandably, Dr. Rooney is one of the most frustrated people I know of. Thousands of navicular horses have been needlessly destroyed since his groundbreaking research. He was just 40 years ahead of his time."

That is all set to change, however, as other researchers and hoof care professionals like Ramey are now presenting evidence that supports Rooney's work. Robert M. Bowker, VMD, PhD, of the ground breaking Equine Foot Laboratory at Michigan State University, agrees with Rooney's assertions

*continued on page 76*

### AN INSIDE LOOK





about the damage caused by toe first landing, plus his own work highlights why such unnatural landing happens, and what we can do about it. He has shown that horses have internal structures in the back part of the foot that under natural conditions, continue to develop from birth through the first few years of the horse's life. These structures, known as the lateral cartilages and the digital cushion, are soft, thin and incomplete in the newborn foal, but become key to the support, protection and overall function of the foot as they become thicker and stronger.

Unfortunately, current shoeing and horsekeeping practices most often prevent the development of these structures, leaving our full grown horses with "baby" feet that are extremely vulnerable to pain and lameness, particularly in the back part of the foot. It is this unnatural and unnecessary sensitivity that leads to toe first landing – and too often, to navicular disease. As Ramey explains, "The back of the foot is supposed to be a solid, but flexible landing zone that can slam into any terrain like the hooves of a wild horse. It often hurts our domestic horses to run a hoof pick along the frogs! This should scare us, but we've learned to cope with this by shoeing the young horse, lifting the frog off the ground and raising the heels. This lifts the sensitive structures off the ground and makes the horse feel better, but ensures the hoof will never develop into something the horse can use to dissipate impact energy like it was supposed to. The horse will always be forced to absorb energy impact with the rigid front of the foot."

### THE TREATMENT IS IN THE TRIM

Fortunately, Dr. Bowker has shown that even adult horses can develop the internal structures of the foot to a great extent. In order for this to happen, however, it is absolutely necessary to get the foot back to the form and function that nature intended. Bowker summarizes this by stating: "If you keep the toe short between the frog apex and the hoof wall, keep the frog and bars on the ground, leave the dirt in the foot [which provides natural support; manure should be removed], plus get the horses out and moving, you'll have a healthy foot most of the time." Bowker, Ramey and others emphasize that it is this trim that makes the greatest difference, whether you shoe the horse or not.

For those interested in a bit more detail, Ramey adds, "The sole should not be trimmed except to sometimes exfoliate shedding or false sole. There should be enough sole depth to lift the collateral grooves (beside the frog) about an inch off the ground. The walls should be kept 1/16th inch longer than the sole and finished with a large bevel or 'mustang roll.' Routine frog trimming should be avoided. It should be left to callus, like the sole. If there is wall flare, breakover should be set exactly where it would be if there were well connected walls.

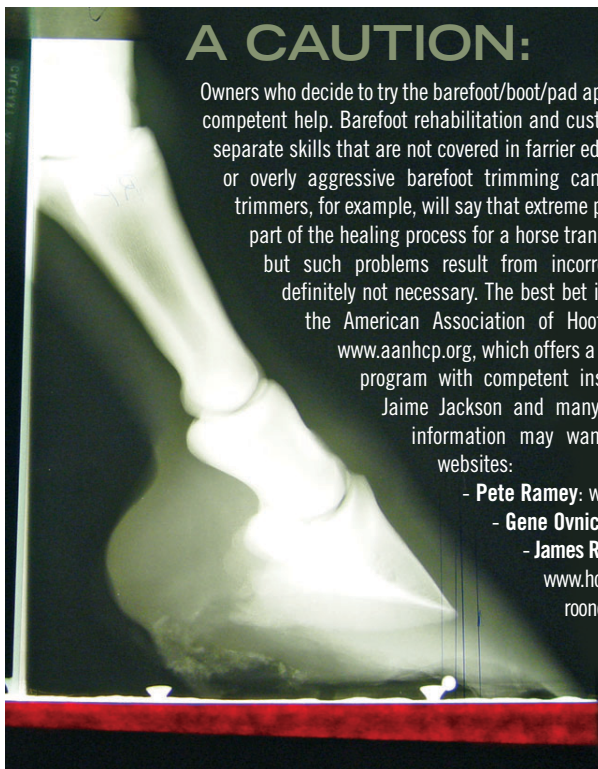
"The hardest and most important part is achieving heel first landing and thus the frog pressure required to finish developing the inner structures. However, if you leave the frog on the ground of a standing navicular horse and the inner structures are weak and undeveloped, the frog may be so sensitive that the horse 'tiptoes' in motion. This will

get you nowhere. Often we have to leave the heels a little longer for a few months. As they sink into footing, they reduce the pressure to the frog; often to a level the horse can and will bear. This reduced pressure allows us to start making progress with digital cushion development. Riding in boots with foam insoles dramatically speeds up this process."

Ramey calls hoof boots with foam inserts "the most magical tools for navicular horses." He says, "I have been able to find a boot and pad combination that makes navicular horses – yes, even those with confirmed bone remodeling – comfortable enough to ride. When you get the trim and the pad combination right, the horse will stride out and load the foot correctly on the second step. Continued exercise in the pads develops the inner structures rapidly, and usually, the pads and boots are soon no longer necessary." He points out that during the initial phase, the horse is by no means healed, "but it can now very comfortably receive the thousands of 'pressure and release' impacts it will need to develop the inner structure an adult horse is supposed to have. That's the difference between doing this with boots and foam pads versus any kind of rigid supports that can only provide pressure, but no release." Ramey makes no claim to being able to reverse bone pathology, just the cause of the pathology and most of the pain. "The main point," he says, "is that we can get these horses happy and back to work – and we can darn sure prevent the problem in the first place."

One dramatic success Ramey has had was a vet-diagnosed, radiographically confirmed navicular horse that also had a significant P3 rotation and sinking due to founder. "The previous owner tried many types of orthopedic shoeing by several farriers, none of which had helped. They drove over 600 miles to see me, so I was especially glad that the horse became sound within a month of the first trim, and three years later, is still sound and working for a living."

Another well documented, recent success is Joey, a horse in the Houston Mounted Patrol that had been diagnosed with navicular disease by a leading university. As Greg Sokoloski, an officer and trainer with the unit recalls, "Joey was the very best horse we had, so we were willing to do whatever was necessary to help him. But after nearly ten months of the traditional orthopedic shoeing, he just wasn't getting better. The last time we took him back to the university, they said he was going to have to be retired. I then asked the vets there about trying a barefoot trim, as I had heard that could be helpful in such situations, but they said that going barefoot would just make him worse."



**A CAUTION:**

Owners who decide to try the barefoot/boot/pad approach should be sure they have competent help. Barefoot rehabilitation and custom boot fitting are specific and separate skills that are not covered in farrier education programs, and incorrect or overly aggressive barefoot trimming can cause severe damage. Some trimmers, for example, will say that extreme pain and abscesses are a normal part of the healing process for a horse transitioning from shoes to barefoot, but such problems result from incorrect, severe trimming and are definitely not necessary. The best bet is to find a professional through the American Association of Hoof Care Practitioners (AANHCP) [www.aanhcp.org](http://www.aanhcp.org), which offers a lengthy and intense certification program with competent instructors such as Pete Ramey, Jaime Jackson and many others. Those seeking further information may want to check out the following websites:

- Pete Ramey: [www.hoofrehab.com](http://www.hoofrehab.com)
- Gene Ovnicek: [www.hopeforsoundness.com](http://www.hopeforsoundness.com)
- James R. Rooney, DVM: [www.horseshoes.com/farriersites/sites/rooney](http://www.horseshoes.com/farriersites/sites/rooney)
- WSU paper on MRI and navicular: [www.ivis.org/proceedings/AAEP/2003/schneider/IVIS.pdf](http://www.ivis.org/proceedings/AAEP/2003/schneider/IVIS.pdf)

But faced with losing Joey from the force, the administration gave Sokoloski permission to try a barefoot trim on him. "We started the barefoot trim," says Sokoloski, "and two weeks later I was riding him. Another two weeks later, we were riding him in one of the biggest, most unruly protests we've had to deal with, and we were sure glad to have him." Joey was sound at that point, but Sokoloski recognized that there was still room for improvement, so he took the horse to Pete Ramey. Says Ramey, "I trimmed the horse in the clinic I was doing there and immediately saw some improvement. Then I fit the horse with boots and foam insoles, and people were cheering at the movement, but my wife Ivy and I could still see a bit of hesitation in his gait. I added foam frog pads to the insoles, and the horse took off like he was floating on air. Big, mean cops had tears in their eyes the size of granny's biscuits. The horse has been happily working ever since."

Officer Sokoloski, who now has 22 barefoot horses in his unit, is tremendously grateful that they were able to save Joey with barefoot trimming and boots, but he remains frustrated by the experience. "It stuns me that we weren't given this option by the veterinary professionals we consulted, at any point. People are told all the time that their horses with navicular are through, and that just doesn't have to be the case. Correct barefoot trimming makes a world of difference – and it shouldn't be the last thing we do. I wish everyone, horse owners and veterinarians alike, could learn from what we went through with Joey."

Not everyone, however, is going to be willing to try the barefoot and boots option, and that's where the work of Gene Ovniczek comes in. Ovniczek, a highly regarded Master Farrier and developer of the Natural Balance shoeing system, shares remarkably similar views to Ramey when it comes to treating navicular disease. Both men assert that the best way to treat and prevent the problem is to achieve correct, heel first landing through physiologically correct trimming based on the hooves of wild horses. Ovniczek openly states his belief that correct barefoot hoof-care is the healthiest option for almost all horses, and that it is the preferable way to treat navicular disease. But, he does recognize that for some horses, that isn't an option, so he has developed a system of trimming and shoeing that he believes is the next best thing.

Ovniczek says, "The way that Pete [Ramey] uses boots and pads is very similar to what we do with our shoes and pads, which are designed to provide protection, yet still allow stimulation, and to promote a heel first landing and correct breakover. We first trim the foot in the most efficient way to restore function, and what we add to it is only a temporary means to relieve the stresses and

strains so that the horses can be more comfortable. The thing that is of paramount importance in our work is that the whole idea of the frog next to the ground and the other requirements of a healthy, functional foot are never left out of anything we do as a treatment modality."

One of the requirements for healthy function that Ovniczek emphasizes is breakover. As he explains, "Most domestic horses have only a moderately functional foot. This is because our whole perception of what we consider a normal foot is actually a distorted foot. The breakover is a big part of that, as well as the lateral movements of the foot. As farriers, we were taught to promote a large foundation under the horse – this was a good

---

**"They drove over 600 miles to see me, so I was especially glad that the horse became sound within a month of the first trim, and three years later, is still sound and working for a living."**

---

thing. But most of what we should have been talking about was producing good heel width. The rest of the foot is a lever that the horse has to move over the top of. So, what we thought was proper, traditional hoof maintenance was actually creating leverages that we're now seeing as being a serious problem."

Facilitating breakover is one of the reasons why Ovniczek believes that using shoes as he does can sometimes help a navicular horse get comfortable more quickly than being barefoot. "What we've found, especially with deep flexor lesions and impar ligament pain, is that the breakover is going to be a huge factor in relieving the strain to get them over the top of their foot," says Ovniczek. "Now, if you can do that bare-

footed that's great, but it is difficult to do because you're limited as to how much you can immediately reduce that breakover on a bare foot." Ovniczek aims to eventually transition a horse out of shoes, but says, "Horses with proper breakover, the frog on the ground, and landing on the back of the foot are going to have basically normal function, regardless of whether they are shod or unshod. The barefooted horse is going to have better function, but the shod horse, especially if the foot is compacted with dirt, can be almost as good."

Like Ramey, Ovniczek believes in the importance of getting the navicular horse comfortable and moving, and in his experience, this should happen fairly quickly. "The idea of a horse being unsound for a year or even longer is, in my opinion and the opinion of many, unnecessary. We most often succeed in a very short period of time simply by putting these horses in a sound state and back to work, and allowing that to work in our favor. If a horse has badly distorted feet – heels curled under, the bars crushed in – just trimming all of that distortion away and getting them back on the ground gives horses tremendous relief right away." Ovniczek adds that this doesn't mean the horses will necessarily be completely sound within the next two to three months, because there may be other factors to consider, such as adhesions of the tendons and ligaments that develop to compensate for hoof distortion issues. "Still," he says, "I can't tell you how many times we've had horses come in that have been suffering, sometimes for a year or two years, and instantly, those horses can go back to work and feel really good about what they're doing."

Though some may doubt the claims of practitioners such as Ovniczek and Ramey, the statements of these pioneers will undoubtedly be music to the ears of many horse owners searching for options after their horses are diagnosed with navicular disease. Ultimately, every owner must decide what treatment options are best for their horses, but it is good to know that progress is being made in the baffling battle against navicular disease.

## Dynamint Equine Leg & Muscle Rub

**2002 BCRA Rookie of the Year, Ronnie Jansen says: "Dynamint helps to keep rodeo horses in top shape. It's cool, soothing effect gives me instant relief and fast healing for my own pain problems as well."**



- natural
- non toxic
- healing
- soothing
- effective
- pleasant minty odour
- won't irritate open wounds
- reduces swelling
- non-greasy
- absorbs quickly
- non-testable
- non-burning
- non-blistering



**Check out our Web site: [www.integratedbiosys.com](http://www.integratedbiosys.com)**

**National Distributor: Canadian Centurion 1-800-361-3860 • Local: Janian Imports (604) 462-9238**

*Manufactured by: Integrated Bio Systems Inc., 34282 Manufacturers Way, Abbotsford, BC V2S 7M1*

*Phone: 1-877-501-5003 • Fax: 604-852-9016 • E-Mail: [imbiosys@shaw.ca](mailto:imbiosys@shaw.ca)*